

Antenatal onset of haemorrhagic and/or ischaemic lesions in preterm infants: prevalence and associated obstetric variables

L S de Vries, P Eken, F Groenendaal, K J Rademaker, B Hoogervorst, H W Bruinse

Abstract

Aim—To assess the prevalence of an antenatal onset of haemorrhagic and/or ischaemic lesions in preterm infants; to identify possibly related obstetric risk factors.

Methods—A prospective cohort study was made of 1332 infants born at less than 34 completed weeks, using cranial ultrasound, for the presence of antenatal brain lesions (group A) involving the periventricular white matter (PVWM) or central grey matter. Entry criteria were presence of (i) cysts in the PVWM < 7 days; (ii) increased PVWM echogenicity < 6 hours, confirmed to be white matter necrosis at post mortem examination; (iii) a unilateral porencephalic cyst < 3 days; (iv) an intraventricular haemorrhage with unilateral parenchymal involvement < 6 hours; and (v) symmetrical areas of increased echogenicity in the thalami, confirmed to be areas of calcification on post mortem examination. Group B consisted of infants with a normal early neonatal ultrasound scan with subsequent development of the lesions mentioned above.

Results—Twenty four cases met the entry criteria for group A: 17 died and five of the seven survivors developed cerebral palsy at follow up. Of the whole cohort, 156 (11.7%) infants died and in 63 (40.3%) of these a large ultrasound lesion was present. In 17 (26.9%) cases this lesion was considered to be of antenatal onset. Sixty eight of the 1176 (5.8%) survivors developed cerebral palsy and this was attributed to antenatal onset in five (7.3%). A comparison of the obstetric risk factors between the infants in group A and B, who either died or developed cerebral palsy, showed a significant difference in gestational age between the two groups (30.9 vs 28.9 weeks; $p < 0.001$). Prolonged rupture of membranes was significantly more common in group B ($p = 0.03$), while an ominous cardiotachogram was significantly more common in group A ($p = 0.01$), and this remained significant following logistic regression analysis.

Conclusions—Although these data suggest that most preterm infants did not develop their brain lesions in utero, an antenatal onset was not uncommon, especially in those with PVWM lesions, who did not survive the neonatal period.

(Arch Dis Child Fetal Neonatal Ed 1998;78:F51-F56)

Keywords: antenatal onset; intracranial lesions; cerebral palsy; periventricular white matter

During the past few years considerable attention has been paid to the possibility of an antenatal onset of intracranial lesions, which can subsequently lead to the development of cerebral palsy during infancy.¹⁻⁴ Initially studies focused on full term infants, emphasising that only 10–20% of the cerebral palsy cases could definitely be attributed to a perinatal or postnatal problem.^{5,6} Recently more attention has been paid to the antenatal onset of intracranial lesions in preterm infants, resulting in the development of cerebral palsy.¹⁻³ In particular large intraventricular haemorrhages (IVH) with parenchymal involvement and extensive cystic periventricular leucomalacia are lesions often associated with an adverse neurological outcome.⁷⁻⁹

Many published case reports detail an antenatal onset of IVH or multicystic encephalomalacia in preterm infants.^{4,10-12} A few larger post mortem studies have also reported a mixed cohort of preterm and full term stillbirths.^{13,14} Recently, Murphy *et al*¹⁵ reported a cohort of preterm infants who died during their first hospital admission. Necropsy findings suggested that extensive white matter damage had been of antenatal onset in 31% of the 83 cases. To date, only two large studies have been published which deal with live born preterm infants with ultrasound abnormalities, present immediately after birth, that suggest an antenatal onset.^{1,3}

The aim of this study was twofold. First, to gain more insight into the prevalence of an antenatal onset of haemorrhagic and/or ischaemic lesions in a cohort of preterm infants with a gestational age of 34 weeks or less, and secondly, to investigate possibly associated obstetric risk factors.

Methods

Between 1 September 1989 and 1 January 1996, 1332 infants with a gestational age of 34 weeks or below were admitted to the neonatal intensive care unit of the Wilhelmina Children's Hospital in Utrecht. All infants were studied prospectively, using cranial ultrasound, for the presence of antenatally acquired haemorrhagic and/or ischaemic lesions, involving the periventricular white matter or central grey matter.

The obstetric history was reviewed by one of us (HWB) and the following data were collected: pre-eclampsia (diastolic pressure \geq

Department of
Neonatology,
Wilhelmina Children's
Hospital, Utrecht, The
Netherlands
L S De Vries
P Eken
F Groenendaal
K J Rademaker

Department of
Medical statistics
B Hoogervorst

Department of
Obstetrics, University
Hospital Utrecht
H W Bruinse

Correspondence to:
Dr LS de Vries
Department of Neonatology
Wilhelmina Children's
Hospital
PO Box 18009
3501 CA Utrecht,
The Netherlands.
Email: l.devries@wvz.azu.nl

Accepted 5 August 1997

90 mm Hg on at least two occasions plus proteinuria > 0.3 g/24 hours); antepartum haemorrhage (after 20 weeks of gestation); placental abruption; emergency caesarean section; prolonged prelabour rupture of membranes (>24 hours); chorioamnionitis; maternal infection (cystitis); twin pregnancy; death of a monozygotic co-twin; any known maternal trauma; polyhydramnios; decreased fetal movements; cardiogram abnormalities and absent end diastolic or reversed flow in the umbilical artery. The mode of delivery was recorded, as well as the infants' condition at birth, including umbilical cord blood acid base analysis and Apgar scores.

Cranial ultrasound scans were performed as soon as possible after admission to the neonatal intensive care unit, using a UM-4 mechanical sector scanner with a rotating scan head (5–7.5–10 MHz transducer). Examinations were performed daily during the first week of life and then twice a week until discharge.

Entry criteria for group A included a diagnosis of an "antenatally acquired" lesion when one of the following criteria were met: cystic lesions in the periventricular white matter, present within the first 7 days of life; increased echogenicity in the periventricular white matter, present within 6 hours of birth, confirmed to be white matter necrosis at post mortem examination or evolving into cystic lesions within the first 7 days of life; unilateral porencephalic cyst diagnosed within the first 3 days of life; unilateral IVH, associated with parenchymal involvement present within 6 hours of birth; symmetrical areas of increased echogenicity in the thalami, present within 6 hours of birth, confirmed at post mortem examination to be areas of calcification.¹⁶

Entry criteria were not met when: white matter necrosis was not confirmed by post mortem studies, or when there was no evolution into cystic lesions within the first 7 days of life or when IVH was noted after 6 hours of age.

Group B comprised children who had a normal ultrasound scan on admission, but subsequently developed any of the lesions mentioned above. They either died or went on to develop cerebral palsy.

The survivors were seen in the follow up clinic at 3, 9, 18 and 24 months of age, corrected for prematurity. Assessment of outcome was made using the Griffiths' mental developmental scale¹⁷ and items from Amiel-Tison and Grenier¹⁸ and Touwen.¹⁹ A developmental quotient below 85 on the Griffiths scale was considered abnormal and cerebral palsy was classified according to the criteria of Hagberg *et al.*²⁰

The results of all comparisons are presented as odds ratios and 95% confidence intervals. The two tailed Fisher's exact test with Yates' correction was used to test for differences between those with antenatal lesions and those with a normal first ultrasound scan with subsequent development of similar brain lesions. A *p* value of less than 0.05 was regarded as significant. Stepwise logistic regression analysis was performed to determine whether the variables

that were found to be significant were independently associated with the two groups.

Results

Only twenty four cases (1.8%) met the entry criteria for group A: six infants had cystic lesions in the periventricular white matter; four infants had early changes compatible with white matter damage, confirmed on histology; three infants showed a porencephalic cyst; five had an IVH with unilateral parenchymal involvement and four had a large IVH with periventricular flaring; two infants had symmetrical echogenic lesions in the thalami.

The infants were divided into four groups with regard to a possibly similar aetiology for their ultrasonographic abnormality (tables 1 and 2).

PROLONGED FETAL DISTRESS (CASES 1–14)

At least two of the following obstetric risk factors were present in six infants (cases 1–6) with a large IVH associated with unilateral parenchymal involvement and ipsilateral thalamic involvement, and in two infants with a large IVH and periventricular flaring (cases 7 and 8): pre-eclampsia; HELLP; decelerations on the cardiogram; absent end diastolic flow on Doppler ultrasound studies; and decreased fetal movements. All were delivered by emergency caesarean section. Gestational age ranged between 27 and 32 weeks. All but two infants did not survive the neonatal period.

Three other infants, cases 9–11, also suffered fetal distress, but had different cranial ultrasound abnormalities. In one case labour had been induced in another hospital at 32 weeks, following the diagnosis of a myelomeningocele. Induction was not successful and spontaneous delivery occurred two weeks later. Extensive white matter damage was present immediately after delivery. In the other two cases decreased fetal movements and decelerations on the cardiogram had been present. In both infants extensive areas of increased echogenicity were present in the periventricular white matter, as well as in the region of the middle cerebral artery in one. All three infants died. A post mortem examination was performed in two and confirmed the ultrasonographic findings.

Two infants born at 27 and 33 weeks, respectively (cases 12 and 13), were delivered by emergency caesarean section, the first because of a placental abruption, the other because of decreased fetal movements, polyhydramnios, and decelerations on the cardiogram. These infants were unable to breathe spontaneously at birth, required vigorous resuscitation, and both showed contractures in hips, knees, and elbows and facial diplegia. Symmetrical areas of increased echogenicity in the thalami were noted on day 1 and this was confirmed to be calcification on computed tomogram and at post mortem examination. These infants were diagnosed as having symmetrical thalamic lesions.¹⁶

One further infant (case 14) was in antenatal distress due to antenatal supraventricular tachycardia, occurring at about 28 weeks of

gestational age and a porencephalic cyst was diagnosed at delivery at 33 weeks.

MULTIPLE PREGNANCY (CASES 15–18)

Four infants were part of a multiple pregnancy. Two cases born at 28 and 31 weeks, respectively, showed extensive periventricular cysts on day 1. Their monozygous co-twins had died two and three weeks earlier. One case, one of monozygous twins, was born by emergency

caesarean section at 34 weeks because of decelerations on the cardiogram, associated with absent diastolic umbilical flow. This twin was noted to have a large left middle cerebral artery infarct with cyst formation present on day 3. The fourth infant was a triplet born at 31 weeks who was noted to have a small infarct in the region of the right middle cerebral artery with cyst formation on day 1. The triplet was delivered by emergency caesarean section

Table 1 Antenatal and perinatal data of the 24 cases with lesions of antenatal onset

	Sex	Gestational age	Birthweight	Antenatal problems/delivery	pH	Apgar
Fetal distress						
1	F	31	720	0 flow/poor CTG/twins/EmCS	7.13	5/8
2	M	30	1305	PET; decreased fetal movement/poor CTG/EmCS	7.08	3/10
3	M	27	770	0 flow/poor CTG/EmCS	7.12	8/9
4	F	30	715	HELLP/0 flow;poor CTG/EmCS	7.16	4/9
5	M	32	960	0 flow/poor CTG/EmCS	7.16	4/8
6	F	30	1060	0 flow/poor CTG/decreased fetal movement/EmCS		1/6
7	F	27	670	HELLP/0 flow/poor CTG/EmCS		4/7
8	M	30	1455	Poor CTG/decreased fetal movement/EmCS	6.93	
9	F	34	2890	Decreased fetal movement/trisomy 21/poor CTG/ vag. vertex		4/6
10	F	34	2560	Failed induction at 32 weeks/MMC/vag. vertex		Good
11	F	32	2500	Polyhydramnios/solutio/vag. vertex		
12	F	27	940	Solutio/EmCS		
13	F	33	1840	Decreased fetal movement/polyhydramnios/poor CTG/EmCS	7.06	3/7
Arythmias						
14	M	33	2140	SVT/vag. vertex	7.40	8/8
Multiple birth						
15	M	28	1140	Death co-twin/EmCS	7.29	5/8
16	M	31	1800	Death co-twin/vag. vertex		9/10
17	M	34	1800	Twins/0 flow/poor CTG/EmCS	7.03	4/7
18	M	31	985	Triplet/CS		9/10
CMV						
19	F	33	1500	IUGR/vag. vertex	7.40	9/10
Coagulopathy						
20	M	31	1670	NAITP/vag. vertex		4/7
Unknown						
21	F	34	1700	Hepatitis A/vag. vertex	7.14	8/9
22	M	33	1305	Decreased fetal movement/poor CTG/EmCS	7.22	4/7
23	M	29	1305	Decreased fetal movement/polyhydramnios/vag. vertex	7.31	
24	M	27	1240	APH/vag. vertex	7.26	3/4

EmCS = emergency caesarean section; MMC = myelomeningocele; SVT = supraventricular tachycardia; PET = pre-eclampsia; IUGR = intrauterine growth retardation; APH = antepartum haemorrhage.

Table 2 Antenatal/perinatal ultrasound findings and outcome of the 24 cases with lesions of antenatal onset

Antenatal ultrasound findings	Age at first ultrasound scan	Ultrasound scan diagnosis	Outcome
Fetal distress			
1	3 h	IVH+PC	Died
2	3 h	IVH+VI	Delay
3	2 h	IVH+VI	Mild hemiplegia
4	3 h	IVH+PVL	Died
5	2 h	IVH+VI	Died
6	3 h	IVH+VI	Died
7	3 h	IVH+VI	Died
8	3 h	IVH+PVL	Died
9	4 h	PVL+MCA Lt	Died/trisomy 21
10 MMC+VD	3 h	PVL	Died
11	3 h	PVL	Died
12	day 1	STL	Died
13	day 1	STL	Died
Arythmias			
14	3 h	IVH+PC Lt	Hemiplegia/shunt
Multiple birth			
15 death co-twin	2 h	c-PVL	Died
16 death co-twin	2 h	c-PVL	Died
17	day 3	MCA Lt	Hemiplegia Rt
18	day 1	MCA Rt	Delay/asymmetry
CMV			
19	day 3	Ca ²⁺ occ. cysts	SND/CP
Coagulopathy			
20	2 h	IVH+PVL	Died
Unknown			
21	day 2	c-PVL	Hemiplegia Rt
22	2 h	PC Lt+c-PVL	Died
23	4 h	PVL	Died
24	3 h	IVH+PVL	Died

IVH = intraventricular haemorrhage; VI = venous infarct; VD = ventricular dilatation; PC = porencephalic cyst; (c)PVL = (cystic)periventricular leucomalacia; MMC = myelomeningocele; MCA = middle cerebral artery; SND = sensorineural deafness; CP = cerebral palsy; MR = mental retardation; CVI = cerebral visual impairment; STL = symmetric thalamic lesions.

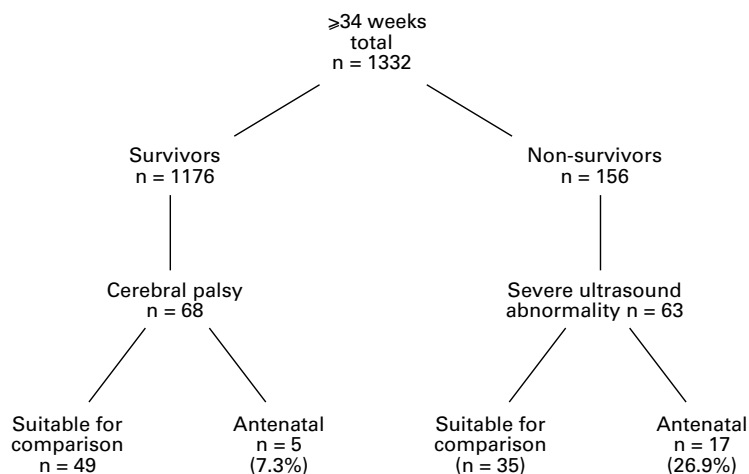


Figure 1 Flow chart of the cohort studied

because of decelerations on the cardiogram in his co-triplet who was severely growth retarded.

CONGENITAL CYTOMEGALOVIRUS INFECTION (CASE 19)

One infant born at 33 weeks had cysts in the occipital periventricular white matter at birth. She was severely growth retarded and microcephalic at birth and was confirmed to have congenital cytomegalovirus infection.²¹

COAGULOPATHY (CASE 20)

One infant born at 31 weeks was noted to have a large IVH and periventricular leucomalacia at birth. The haemoglobin concentration at delivery was 2.9 mmol/l with a platelet count of $18 \times 10^9/l$. Further investigations showed that neonatal alloimmune thrombocytopenia was the underlying problem.

UNKNOWN AETIOLOGY (CASES 21–24)

In the remaining four infants no definite aetiology could be established. The infants had a gestational age of 27, 29, 33 and 34 weeks, respectively. One had a lethal skin disorder (restrictive dermopathy); polyhydramnios and decreased fetal movements had been present before delivery. Extensive areas of increased echogenicity of the periventricular white matter were present at birth. The second case was delivered by caesarean section because of decreased fetal movements and variable decelerations on the cardiogram. Ultrasound scans showed periventricular calcifications, a porencephalic cyst, and an isolated subcortical cyst in the other hemisphere. No congenital infection was identified. In the third case the mother had hepatitis A infection during the second trimester and the infant had unilateral periventricular cystic lesions at birth. The last case was delivered vaginally, had a poor Apgar score, and was diagnosed as having a large IVH with substantial periventricular echodensities at 3 hours of age.

NEURODEVELOPMENTAL OUTCOME

Seventeen of the 24 (70.8%) infants died and ultrasound abnormalities were confirmed in the seven cases in whom permission for post

Table 3 Reasons for exclusion of infants in the comparison group

Reason for exclusion	Survivors	Non-survivors
Referral > 6 h	9	7
IVH without Par. involvement	2	3
PVE day 1, cysts > day 7	3	0
PVE day 1, no post mortem	0	1
Total	14	11

mortem examination had been obtained. Of the seven surviving infants, one preterm infant with IVH and unilateral parenchymal and thalamic involvement had a noticeable speech delay at 3 years of age. One preterm infant with a localised infarct in the region of the middle cerebral artery had a borderline developmental quotient at 2 years of age. The remaining five infants developed cerebral palsy, which was associated with mental retardation in two.

OBSTETRIC RISK FACTORS FOR INTRACRANIAL LESIONS DEVELOPED ANTENATALLY OR PERINATALLY

During this six year period 68 of the 1176 survivors (5.8%) developed cerebral palsy attributed to an antenatal onset in five cases (7.3%) (fig 1). In a further 14 cases (table 3), a severe ultrasound abnormality was noted on the first scan, but the entry criteria were not met as the IVH was restricted to the lateral ventricle in two and the scan was performed after 6 hours of age in nine cases with an IVH with parenchymal involvement; in the other three cases with leucomalacia, increased periventricular echogenicity was noted on day 1, but cysts were first noted after the end of the first week of life. Of these 63 perinatal cases, only 49 could therefore be used for comparison of obstetric risk factors.

One hundred and fifty six infants (11.7%) died during this six year period. In 63 of these 156 infants (40.3%) a large haemorrhagic and/or ischaemic lesion was present on ultrasound scan. In 17 (26.9%) of them these lesions occurred before birth. In a further 11 cases a large haemorrhage was noted on the first ultrasound examination, but in three infants the entry criteria were not met as the blood was restricted to the ventricular system; in seven the first scan was performed between 6 and 24 hours of age, and in one case white matter damage was noted but not confirmed as permission for post mortem examination was not obtained. Of these 46 perinatal cases, only 35 could therefore be used for comparison.

Twenty two infants with a definite antenatally acquired lesion who either died or went on to develop cerebral palsy were thus compared with 84 cases (49 survivors and 35 non-survivors) in whom the first ultrasound scan did not show any major ultrasound abnormalities, or where periventricular cysts developed after the first week of life.

Mean gestational age at birth was significantly higher for the antenatal cases (mean 30.9; range 27–34) than for the perinatal cases (mean 28.9; range 25–34) ($p < 0.001$).

Antenatal complications were common in both groups. Prolonged rupture of membranes was significantly more common among the

Table 4

Factor	Group A antenatal cases (n=22)	Group B perinatal cases (n=84)	Odds ratio (95% CI) for death or CP	P value
Gestational age	30.9 (27-34)	28.9 (25-34)		0.001
Antenatal complications				
Multiple pregnancy	4 (18.2%)	25 (29.8%)	1.91 (0.58-6.2)	NS
Pre-eclampsia	4 (18.2%)	16 (19%)	1.06 (0.31-3.56)	NS
APH	3 (13.6%)	18 (21.4%)	1.72 (0.46-6.49)	NS
PROM	2 (9.1%)	28 (33.1%)	4.74 (1.03-21.7)	0.03
Chorioamnionitis	2 (9.1%)	19 (22.6%)	2.72 (0.58-12.7)	NS
Antenatal investigations				
CTG				
Performed	18 (81.8%)	58 (69.9%)		NS
Ominous	13 (72.2%)	21 (36.2%)	0.22 (0.07-0.69)	0.01
Delivery				
Vaginal vertex	10 (45.5%)	35 (41.7%)	0.86 (0.33-2.2)	NS
Vaginal breech	0	11 (13.1%)	—	NS
Emergency CS	12 (54.5%)	31 (36.9%)	0.48 (0.19-1.26)	NS
Condition at birth				
Umbilical pH performed	14 (63.6%)	40 (47.6%)		NS
PH < 7.10	3 (21.4%)	4 (10%)	0.41 (0.08-2.11)	NS
Apgar ≤ 3 at 1 min	4 (18.2%)	23 (27.4%)	1.69 (0.51-5.5)	NS
Apgar ≤ 5 at 5 min	2 (9.1%)	11 (13.1%)	1.51 (0.31-7.3)	NS

infants who developed their ultrasound abnormalities during the first week of life ($p=0.03$). A significantly higher number of the antenatal cases had an ominous cardiogram ($p=0.01$), and all but one of these cases was delivered by emergency caesarean section.

After stepwise logistic regression analysis only an ominous cardiogram remained significant ($P=0.01$).

Discussion

In this cohort of preterm infants with a gestational age of 34 weeks or below, studied in a tertiary intensive care unit during a six year period, definite antenatal onset of haemorrhagic and/or ischaemic lesions was established in 1.8%. This prevalence seems low, but it has to be remembered that no ultrasound abnormalities were present in 46% of the children in this cohort. It is therefore of greater importance to establish that five of the 68 infants (7.3%) who survived and went on to develop cerebral palsy in infancy and 17 of the 63 cases (26.9%) who died with a similar type of haemorrhagic/ischaemic lesion met the criteria of an antenatally acquired lesion. Furthermore, the number of antenatal cases is probably higher, but several infants could not be included as they either presented with only an intraventricular haemorrhage ($n=5$) or they had associated parenchymal involvement but were admitted after the first 6 hours of age ($n=16$), which made it impossible to be certain about the antenatal onset. If, for instance, all nine surviving cases with parenchymal involvement diagnosed on the first scan, performed after 6 hours, were considered to be of antenatal onset, this would raise the prevalence of 7.3% (5/68) to 20% (14/68).

When looking at the aetiology of these antenatal brain lesions, prolonged fetal distress was noted to be most common. In four infants a similar ultrasound picture was found immediately after birth, which has so far not been reported. These infants had a large intraventricular haemorrhage, associated with both unilateral parenchymal involvement as well as ipsilateral involvement of the thalamus. Severe pre-eclampsia, associated with decreased fetal

movements and an ominous cardiogram and/or absent end diastolic flow, with subsequent delivery by emergency caesarean section, was noted in all. Prolonged fetal distress was present in 11 other cases, but with different intracranial pathology on ultrasound scan. In two infants who had symmetrical thalamic lesions, confirmed to be areas of calcification on post mortem examination, acute rather than prolonged fetal distress probably preceded these lesions.¹⁶

Multiple pregnancy was present in four of the antenatal cases, with death of a monozygous co-twin in two.²² The third set of twins was also monozygous and the smaller one, who showed signs of fetal distress on cardiogram and Doppler ultrasound, had a large cystic middle cerebral artery infarction evident on ultrasound scan after birth. The last one was a triplet and the reason for the antenatal infarct in this infant remains unclear, as the emergency caesarean section was performed for fetal distress in his brother. In one infant coagulopathy due to neonatal alloimmune thrombocytopenia was the probable cause of the large intraventricular haemorrhage.²³

In four infants the aetiology remains uncertain. In the case with a lethal skin disorder prolonged fetal distress seems the most likely explanation, while in the third case it cannot be excluded that the maternal hepatitis infection earlier in pregnancy might have contributed to the development of brain lesions.

The outcome of the group with antenatal lesions was poor: 17 of the 24 infants died and none of the survivors was completely developmentally normal at follow up.

Antenatal and perinatal risk factors were compared in those with a haemorrhagic/ischaemic lesion of definite antenatal onset and those who had a normal first ultrasound scan and subsequently developed a similar brain lesion. The infants with an established lesion at birth were significantly more mature than those who developed this lesion after birth (30.9 *vs* 28.9 weeks). This is not surprising as some of the antenatal lesions, like the death of a co-twin, could be accurately timed and occurred two and three weeks before birth. In other children, however, for example those with haemorrhagic parenchymal involvement or increased echogenicity in the periventricular white matter, the intracranial lesion probably occurred less than 48 hours before delivery.

In spite of the fact that the insult had occurred sometimes several weeks before delivery, with the lesion being well established at birth, significantly more abnormal tracings were recorded among the antenatal cases, resulting in an emergency caesarean section in all but one of them. This finding is important in terms of the ever increasing number of medico-legal cases. Prolonged rupture of membranes, however, was significantly more common among the infants who developed ultrasound lesions during the neonatal period. This finding agrees with several recent studies in which an association was found between premature rupture of the membranes and IVH,

periventricular leucomalacia, or cerebral palsy.²⁴⁻²⁶

While we grouped together infants who survived with cerebral palsy with infants who died, but who had severe intracranial pathology on cranial ultrasound, previous studies have either looked at survivors with cerebral palsy or at infants who were either stillborn or died early. It is therefore difficult to compare our data with those of other studies. Bejar *et al*¹ prospectively studied 127 preterm infants with a gestational age < 36 weeks to determine the incidence of white matter necrosis and found a very high incidence of 10.3% of children who had cysts by day 3. Stepwise logistic regression identified placental vascular anastomoses in multiple pregnancy, funisitis, and purulent amniotic fluid as significant risk factors. Murphy *et al*³ studied a cohort of singletons born before 33 weeks between 1987 and 1990. They excluded those who died and matched 18 cerebral palsy cases with controls. None of the infants had cysts by day 3, six developed cysts by day 10, and two of these had periventricular echodensities on the first postnatal scan. They concluded that intrauterine factors may have contributed to the adverse neurological outcome, but that most of the infants developed their intracranial brain lesion in the perinatal period.

Several large pathology studies have been reported recently, showing a wide variation of white matter damage in stillborn infants from less than 2%²⁷ up to 40%.¹³ In one study¹⁴ microscopic evidence of ischaemic cerebral injury was found in 31% of the stillborn infants and this was commonly associated with placental infarcts. In another study an association was noted with acute intrauterine infection.²⁸

In a recent study by Murphy *et al*¹⁵ who studied a cohort of 83 very preterm infants who died, 57% had evidence of cerebral damage and this was considered to be of antenatal onset in 31%. This is very similar to the 26.9% noted in our study. Not all their cases had cranial ultrasound examinations and a lesion was defined as being of antenatal onset on the basis of the pathology findings.

In conclusion, the total number of preterm infants who either died or developed cerebral palsy following the development of a haemorrhagic and/or ischaemic lesion, acquired well before birth, was small, suggesting that most preterm infants do not develop their brain lesions in utero. However, some antenatal factors, such as prolonged prelabour rupture of membranes, may be associated with postnatal onset of certain brain lesions, or may make the brain more vulnerable to subsequent insults in the neonatal period.

- 1 Bejar R, Wozniak P, Allard M, *et al*. Antenatal origin of neurologic damage in newborn infants. I. Preterm infants. *Am J Obstet Gynecol* 1988;159:357-63.
- 2 Murphy DJ, Sellers S, MacKenzie IZ, Yudkin PL, Johnson AM. Case-control study of antenatal and intrapartum risk factors for cerebral palsy in very preterm singleton babies. *Lancet* 1995;346:1449-54.
- 3 Murphy DJ, Hope P, Johnson AM. Ultrasound findings and clinical antecedents of cerebral palsy in very preterm infants. *Arch Dis Child* 1996;74:F105-9.
- 4 Scher MS, Belfar H, Martin J, Painter MJ. Destructive brain lesions of presumed fetal onset: antepartum causes of cerebral palsy. *Pediatrics* 1991;88:898-906.
- 5 Blair E, Stanley FJ. Intrapartum asphyxia: a rare cause of cerebral palsy. *J Pediatr* 1988;112:515-19.
- 6 Nelson KB, Leviton A. How much of encephalopathy is due to birth asphyxia? *Am J Dis Child* 1991;145:1325-31.
- 7 De Vries LS, Dubowitz LMS, Dubowitz V, *et al*. Predictive value of cranial ultrasound: a reappraisal. *Lancet* 1985;ii:137-40.
- 8 Graham M, Levene MI, Trounce JQ, Rutter N. Prediction of cerebral palsy in very low birth weight infants: prospective ultrasound study. *Lancet* 1987;ii:593-6.
- 9 Pinto-Martin J, Riolo S, Cnaan A, Holzman C, Susser MW, Paneth N. Cranial ultrasound prediction of disabling and non-disabling cerebral palsy at age two in a low birth weight population. *Pediatrics* 1995;95:249-54.
- 10 Murdoch Eaton DG, Ahmed Y, Dubowitz LMS. Maternal trauma and cerebral lesions in preterm infants. *Br J Obstet Gynecol* 1991;98:1292-4.
- 11 Baethmann M, Kahn T, Lenard H-G, Voit T. Fetal CNS damage after exposure to maternal trauma during pregnancy. *Acta Paediatr* 1996;85:1331-8.
- 12 Fogarty K, Cohen HL, Haller JO. Sonography of fetal intracranial hemorrhage: unusual causes and a review of the literature. *J Clin Ultrasound* 1989;17:366-70.
- 13 Squier M, Keeling JW. The incidence of prenatal brain injury. *Neuropathol Applied Neurobiol* 1991;17:29-38.
- 14 Burke CJ, Tannenbaum AE. Prenatal brain damage and placental infarction - an autopsy study. *Dev Med Child Neurol* 1995;37:555-62.
- 15 Murphy DJ, Squier MV, Hope PL, Sellers S, Johnson AM. Clinical associations and time of onset of cerebral white matter damage in very preterm babies. *Arch Dis Child* 1996;75:F27-F32.
- 16 Eicke E, Briner J, Willi U, Uehlinger J, Boltshauser E. Symmetrical thalamic lesions in infants. *Arch Dis Child* 1992;67:15-19.
- 17 Griffiths R. *The abilities of babies: a study in mental measurement*. Amersham: Association of Research in Infant and Child Development, 1976.
- 18 Amiel-Tison C, Grenier A. *Evaluation neurologique du nouveau-né et du nourrisson*. Paris: Masson, 1980.
- 19 Touwen BLC. Examination of the child with minor neurological dysfunction. *Clinics in Developmental Medicine No 71*. London: SIMP/Heinemann, 1979.
- 20 Hagberg B, Hagberg G, Olow I. The changing panorama of cerebral palsy in Sweden 1954-1970. II, analysis of various syndromes. *Acta Paediatr Scand* 1975;64:193-200.
- 21 Boesch C, Issakainen G, Kewitz R, Kikinis R, Martin E, Boltshauser E. Magnetic resonance imaging of the brain in congenital cytomegalovirus infection. *Pediatr Radiol* 1989;19:91-3.
- 22 Larroche JC, Droullé P, Delezoide AL, Nancy F, Nessmann C. Brain damage in monozygous twins. *Biol Neonate* 1990;57:261-78.
- 23 De Vries LS, Connell JA, Bydder GM, *et al*. Recurrent in utero intracranial haemorrhage in an infant with allo-immune thrombocytopenia. *Br J Obstet Gynecol* 1988;95:299-302.
- 24 Perlman JM, Risser R, Broyles RS. Bilateral cystic periventricular leukomalacia in the premature infant: associated risk factors. *Pediatrics* 1996;97:822-7.
- 25 Spinillo A, Capuzzo E, Stronati M, Ometto A, Orcesi S, Fazzi E. Effect of preterm premature rupture of membranes on neurodevelopmental outcome: follow-up at two years of age. *Br J Obstet Gynecol* 1995;102:882-7.
- 26 Mercer BM, Arheart KL. Antimicrobial therapy in expectant management of preterm premature rupture of the membrane. *Lancet* 1995;346:1271-9.
- 27 Roland H, Norman MG, Hill A. Antenatal periventricular white matter infarction. *Ann Neurol* 1987;22:423(A).
- 28 Sims ME, Beckwith-Turkel S, Halterman G, Paul RH. Brain injury and intrauterine death. *Am J Obstet Gynecol* 1985;151:721-3.



Antenatal onset of haemorrhagic and/or ischaemic lesions in preterm infants: prevalence and associated obstetric variables

L S de Vries, P Eken, F Groenendaal, et al.

Arch Dis Child Fetal Neonatal Ed 1998 78: F51-F56
doi: 10.1136/fn.78.1.F51

Updated information and services can be found at:
<http://fn.bmj.com/content/78/1/F51.full.html>

- These include:*
- References** This article cites 25 articles, 5 of which can be accessed free at:
<http://fn.bmj.com/content/78/1/F51.full.html#ref-list-1>
- Article cited in:
<http://fn.bmj.com/content/78/1/F51.full.html#related-urls>
- Email alerting service** Receive free email alerts when new articles cite this article. Sign up in the box at the top right corner of the online article.
-

- Topic Collections** Articles on similar topics can be found in the following collections
- [Clinical diagnostic tests](#) (437 articles)
 - [Radiology](#) (420 articles)
 - [Radiology \(diagnostics\)](#) (389 articles)
 - [Child health](#) (992 articles)
 - [Obstetrics and gynaecology](#) (199 articles)
 - [Oncology](#) (127 articles)
 - [Infant health](#) (591 articles)
 - [Neonatal health](#) (636 articles)
 - [Cerebral palsy](#) (55 articles)
 - [Epidemiologic studies](#) (529 articles)
-

Notes

To request permissions go to:
<http://group.bmj.com/group/rights-licensing/permissions>

To order reprints go to:
<http://journals.bmj.com/cgi/reprintform>

To subscribe to BMJ go to:
<http://group.bmj.com/subscribe/>