

Malignant infantile osteopetrosis presenting with neonatal hypocalcaemia

Madhusudan Srinivasan, Mario Abinun, Andrew J Cant, Kelvin Tan, Anthony Oakhill, Colin G Steward

Abstract

Presentation characteristics were reviewed in 14 children from 12 families with malignant infantile osteopetrosis seen at two large referral centres for bone marrow transplantation. Children from six of these families presented initially with symptoms of hypocalcaemia. These comprised early or late neonatal convulsions in six cases (corrected serum calcium < 1.5 mmol/l), and vomiting and irritability (serum calcium 1.68 mmol/l) in another. One other related child had severe and persistent jittering episodes almost certainly attributable to hypocalcaemia. In seven of eight cases, these symptoms developed during the first 14 days of life. Although occasionally reported previously, malignant infantile osteopetrosis remains essentially unrecognised as a cause of neonatal hypocalcaemia, often resulting in diagnostic confusion and delay. This is important in the context of curative haemopoietic stem cell transplantation where preservation of sight may depend on early intervention.

(Arch Dis Child Fetal Neonatal Ed 2000;83:F21–F23)

Keywords: neonatal; hypocalcaemia; malignant infantile osteopetrosis; bone; osteosclerosis; visual impairment

Malignant infantile osteopetrosis (MIOP) is a rare inherited bone disease characterised by reduced or dysregulated activity of osteoclasts, resulting in generalised osteosclerosis (fig 1A).¹ Overgrowth of cranial nerve foramina and the foramen magnum results in nerve compression—progressively affecting the optic, facial, oculomotor, and auditory nerves—and hydrocephalus.² Other problems include irritability, snuffing because of disruption of nasal architecture,^{3–4} hepatosplenomegaly (the result of extramedullary haemopoiesis), and eventually hypersplenism. Failure to thrive and increased infections because of an unexplained defect in neutrophil superoxide function are also characteristic.⁵

In the natural course of the disease, 70% of children die within the first six years.⁶ Most of the remainder have a very poor quality of life and die by the age of 10. With the exception of a very small proportion of cases characterised by primary neurodegenerative disease,^{7–11} bone marrow transplantation (BMT) is curative, as osteoclasts are derived from bone marrow precursors. About two thirds of children are cured by BMT from matched sibling donors.¹² Historically, the use of alternative (non-sibling)

donors has yielded very poor results because of a combination of high rejection rates and other transplant complications. However, there are now encouraging signs that the use of high dose, highly T lymphocyte depleted, parental marrow or peripheral blood stem cell transplants can improve outcome for those lacking a family donor (W Friedrich and T Klingebiel, personal communication).

The commonest presentations result from optic nerve compression in the first year of life.⁶ This may result in failure to establish fixation and nystagmus, or slightly later development of strabismus.¹³ Unfortunately, one of the most disappointing aspects of transplantation is the rarity of reversal of these symptoms.¹² Therefore it is crucial to identify affected children at the earliest possible stage and to perform BMT with relative urgency. This is particularly true now that suitable donors (either sibling or haploidentical) can be found for all patients with only minimal delay.

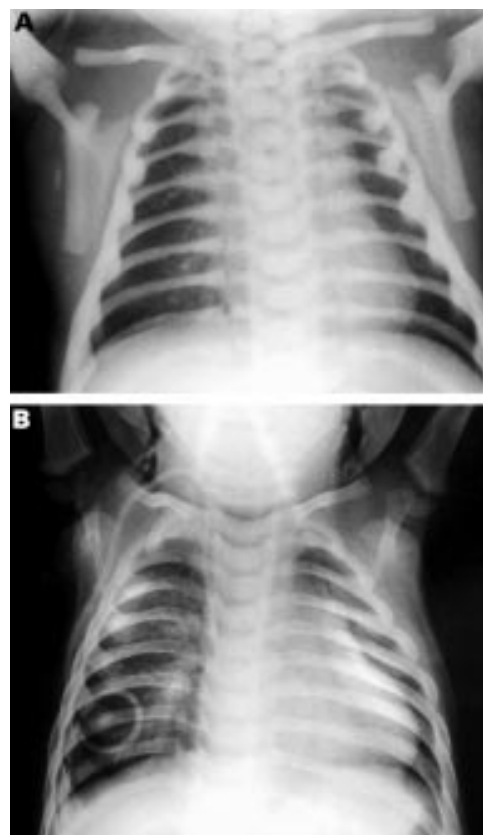


Figure 1 Representative chest radiographs before and after successful unrelated donor bone marrow transplantation. At diagnosis (A) there is generalised osteosclerosis. There is appreciable improvement in both bone density and modelling by nine months after the transplant (B).

Bone Marrow Transplant Unit, Bristol Royal Hospital for Sick Children, Bristol, UK
M Srinivasan
A Oakhill
C G Steward

Children's Bone Marrow Transplantation Unit, Newcastle General Hospital, Newcastle upon Tyne, UK
M Abinun
A Cant

Department of Child Health, University Hospital of Wales, Cardiff, Wales, UK
K Tan

Correspondence to:
Dr Steward, BMT Unit,
Bristol Royal Hospital for Sick Children, St Michael's Hill, Bristol BS2 8BJ, UK
email:
colin.steward@nildram.co.uk

Accepted 9 November 1999

Table 1 Characteristics of presentation in children with hypocalcaemia secondary to malignant infantile osteopetrosis

UPN	Age when hypocalcaemic (days)	Initial symptoms	Age at diagnosis (days)	Additional features at diagnosis
1	1	Focal convulsion	1	
2	4	Focal fitting Snuffling	10	
3B	5	Generalised convulsion	2	
3A	<14	Severe jittering during first 2 weeks	60	Macrocephaly Visual failure Hepatosplenomegaly
4	8	Poor feeding Twitching Brief "spasms"	76	Visual failure Anaemia Macrocephaly Snuffling
5B	10	Jaundice Vomiting Snuffling	30	
6	14	Generalised convulsions	210	Visual failure Anaemia Hepatosplenomegaly Macrocephaly Snuffling
5A	43	Snuffling Generalised convulsions	43	

When there were two affected children within a family, these are denoted A or B according to their order of birth. Child 3B was diagnosed by routine x ray examination on day 2 because of the previous family history.
UPN, unique patient number.

Our report highlights the finding of early or late neonatal hypocalcaemia as the first symptom in eight children presenting with this disease to two large regional referral units for BMT over the past decade. Despite this observation, MIOP is not included in the differential diagnosis of neonatal hypocalcaemia in any current major textbook of paediatrics, an omission that clearly needs correction.

Patients and methods

PATIENTS

Fourteen patients from 12 families presented or were referred to the Bristol Royal Hospital for Sick Children (nine cases) or the Newcastle General Hospital (five cases) between 1983 and 1997. The diagnosis of MIOP was based on typical disease features, such as visual failure or hepatosplenomegaly, together with typical appearances on radiography (fig 1A). Additional bone biopsy was performed in seven children.

Children from six families had hypocalcaemic presentations. The racial origin of these families was as follows: white (four families), Asian (one family) and Arabic (one family). They came from scattered locations within England (four) and Scotland (one); one child was born in Wales to a family from Oman.

BIOCHEMICAL ANALYSES

Table 1 gives age at presentation and clinical features of children presenting with hypocal-

caemia, ranked according to age at first symptomatic presentation. Table 2 gives details, where available, of plasma corrected calcium, together with plasma phosphate, alkaline phosphatase, parathormone, and 25-hydroxyvitamin D assays.

Although recorded in the medical notes as being hypocalcaemic when presenting with convulsions, laboratory results are no longer available in UPN 2. Patient UPN 3A (the sibling of UPN 3B who had late neonatal convulsions) had severe and persistent jittering episodes during the first two weeks of life. These were a common cause of complaint to the family's health visitor and are presumed to have been secondary to hypocalcaemia, although blood tests were never performed.

HYPOCALCAEMIC FEATURES

Six children presented with hypocalcaemic convulsions (corrected plasma calcium < 1.7 mmol/l) between day 1 and 43 of life. In only one of these (UPN 6) was a cause suggested (maternal hypovitaminosis D). A further child presented with physiological jaundice, vomiting, and snuffling at 10 days of age but was found to have a serum calcium of 1.68 mmol/l. The presence of a previous child with MIOP in this family had led to attempted antenatal diagnosis by third trimester radiography,¹⁴ but this was unremarkable. Hypocalcaemia prompted further radiography and hence diagnosis.

Including the child with jittering episodes, eight of 14 children therefore had definite or presumed symptomatic hypocalcaemia during the first month of life. The diagnosis of MIOP was quickly established or already known in five of these eight cases. However, in the remaining children, diagnosis was delayed by 50, 68, and 200 days, by which time all three had developed visual failure.

Mean age at presentation for children with proven hypocalcaemia was 12.4 days. This contrasted with an average of 6.6 months for children presenting with more widely recognised symptoms—for example, nystagmus, hepatosplenomegaly, macrocephaly, and cytopenias.

BONE MARROW TRANSPLANTATION

Ten children underwent BMT at the Bristol Royal Hospital for Sick Children, Newcastle General Hospital, or Hospital for Sick Children, Great Ormond Street; in seven the bone marrow was from unrelated donors, in one it was from a haploidentical donor, in one from a matched sibling, and another from a one anti-

Table 2 Biochemical parameters at presentation

UPN	Gestation	Corrected serum calcium (mmol/l)	Serum phosphate (mmol/l)	Alkaline phosphatase (units/l)	Serum parathormone (pg/ml)	Serum 25OH vitamin D (nmol/l)
1	38/40	1.3	1.79	345	28.7	39
3B	Full term	1.43	1.56	206	3.2	36.3
4	38/40	1.0	NA	NA	210	NT
5A	38/40	1.41	1.3	101	NT	NT
5B	38/40	1.68	0.96	672	42.9	20
6	Full term	1.40	1.52	216	105	13.9

Results are no longer available in patient UPN 2, although hypocalcaemic convulsions were well documented. Blood tests were not performed in patient 3A.

UPN, unique patient number; NT, not tested; NA, not available.

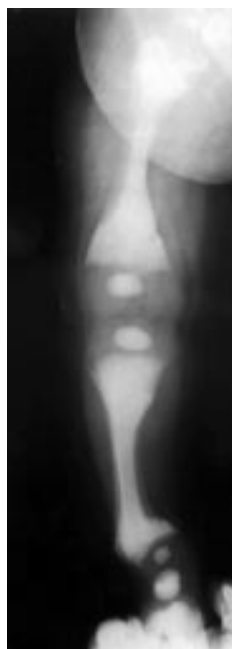

Figure 2 Plain radiograph of right lower limb showing generalised osteosclerosis and a "bone within a bone" appearance. The metaphyses are irregular and there is varus deformity of the distal tibia and proximal femur. These are characteristic appearances of osteopetrosis and secondary rickets.

gen mismatched sibling. Only two survive: one who received a matched sibling transplant at 6 months of age and the other a T cell depleted matched unrelated donor transplant at 6 weeks. Both patients have normal bone density, visual acuity and fields, and are free of all symptoms of disease three and five years after the transplantation. The second of these patients has a strabismus, thought to be familial in origin and improving with age.

Discussion

Disturbance of calcium homeostasis has been well described in MIOP. The first description may have been that by Avery *et al*,¹⁵ who described a baby born with osteopetrosis in 1956 who was a "bit twitchy" at 6 days of age. Subsequently, in a large survey of European patients, Gerritsen *et al*⁶ reported 23 children who had serum calcium measured at presentation. Three children (from separate families) presented with convulsions at less than 1 month of age and had serum calcium levels of < 1.5 mmol/l. Seven others had levels of 1.5–2.0 mmol/l.

In the neonatal period, children are functionally relatively hypoparathyroid. In this setting, normal osteoblast function, unbalanced by compensatory osteoclast function, pushes some osteopetrotic children into hypocalcaemia. The impact of this relative imprisonment of calcium stores is shown most neatly by the development of early rickets in some children (fig 2).^{16 17} This has been elegantly termed a "paradox of plenty".¹⁷ Our series, in conjunction with the observations of Avery *et al* and Gerritsen *et al*, show that this window during which MIOP presents with hypocalcaemia is very narrow—all cases have occurred within the first 43 days, most within the first two weeks.

It could be argued that the high incidence of hypocalcaemic presentation seen in this series reflects a common ancestry. However, the geographical distribution and family histories lend no support to this hypothesis. Clearly, genetic analysis would help to exclude such a founder defect. However, the quest for gene defects responsible for human osteopetrosis is currently proving elusive (in contrast with animal models in which a variety of gene defects—for example, CSF-1, c-src—have been established).¹⁸ This may reflect the presence of a number of separate defects all resulting in osteoclast dysfunction.

The importance of early diagnosis and treatment cannot be stressed too highly. Both of the patients who are alive in this series were transplanted by 6 months of age and retain perfect vision. Furthermore, although established optic atrophy is irreversible, there are well documented cases of visual improvement after transplant.^{12 19} These are presumably children in whom occlusion of the vascular supply to the optic nerve is compromised by bony overgrowth but not yet critically occluded.

With the advent of increasingly safe and refined techniques of haploidentical stem cell transplantation, which for the first time brings the possibility of rapid treatment for most children, early diagnosis is paramount. The absence of MIOP from the differential diagnosis of neonatal hypocalcaemia contributed in this series to a diagnostic delay of up to six months. This oversight must be corrected if this is to be avoided and the chances of transplantation to preserve visual and other cranial nerve function maximised. We therefore recommend that a plain radiograph of the knee or wrist be included in the routine investigation of children with "idiopathic" neonatal hypocalcaemia.

We thank Dr Janet Stone and Mrs Angela Brimble for help with specimens, Professor David Davies and Drs Mike Williams, Thomas Turner, and Tim French for patient referrals and clinical details, and Dr David Grier for sample radiographs. We particularly wish to record the important contribution of Dr Marius Lemon who died before he could see this project completed and is missed greatly by many colleagues in Bristol.

- Singer FR, Chang SS. Osteopetrosis. *Semin Nephrol* 1992;12:191–9.
- Shapiro F. Osteopetrosis. Current clinical considerations. *Clin Orthop* 1993;294:34–44.
- Elster AD, Theros EG, Key LL, Chen MY. Cranial imaging in autosomal recessive osteopetrosis. Part I. Facial bones and calvarium. *Radiology* 1992;183:129–35.
- Bartynski WS, Barnes PD, Wallman JK. Cranial CT of autosomal recessive osteopetrosis. *American Journal of Neuroradiology* 1989;10:543–50.
- Key LL, Ries WL, Rodriguiz RM, Hatcher HC. Recombinant human interferon gamma therapy for osteopetrosis. *J Pediatr* 1992;121:119–24.
- Gerritsen EJ, Vossen JM, van Loo IH, *et al*. Autosomal recessive osteopetrosis: variability of findings at diagnosis and during the natural course. *Pediatrics* 1994;93:247–53.
- Fitch N, Carpenter S, Lachance RC, *et al*. Prenatal axonal dystrophy and osteopetrosis. *Arch Pathol* 1973;95:298–301.
- Ambler MW, Trice J, Grauerholz J, O'Shea PA. Infantile osteopetrosis and neuronal storage disease. *Neurology* 1983;33:437–41.
- Jagadha V, Halliday WC, Becker LE, Hinton D. The association of infantile osteopetrosis and neuronal storage disease in two brothers. *Acta Neuropathologica* 1988;75:233–40.
- Takahashi K, Naito M, Yamamura F, *et al*. Infantile osteopetrosis complicating neuronal ceroid lipofuscinosis. *Pathology, Research and Practice* 1990;186:697–706.
- Abinun M, Newson T, Rowe PW, Flood TJ, Cant AJ. Importance of neurological assessment before bone marrow transplantation for osteopetrosis. *Arch Dis Child* 1999;80:273–4.
- Gerritsen EJ, Vossen JM, Fasth A, *et al*. Bone marrow transplantation for autosomal recessive osteopetrosis. A report from the working party on inborn errors of the European Bone Marrow Transplantation Group. *J Pediatr* 1994;125:896–902.
- Ainsworth JR, Bryce IG, Dudgeon J. Visual loss in infantile osteopetrosis. *J Pediatr Ophthalmol Strabismus* 1993;30:201–3.
- Ogur G, Ogur E, Celasun B, *et al*. Prenatal diagnosis of autosomal recessive osteopetrosis, infantile type, by X-ray evaluation. *Prenat Diagn* 1995;15:477–81.
- Avery ME, Dorst JP, Walker DG. Osteopetrosis. In: Bergsma D, ed. *Clinical Delineation of Birth Defects. IV. Skeletal Dysplasia*. New York: Mosby, 1969:305–11.
- Oliveira G, Boechat MI, Amaral SM, Young LW. Osteopetrosis and rickets: an intriguing association. *American Journal of Diseases of Children* 1986;140:377–8.
- Kaplan FS, August CS, Fallon MD, Gannon F, Haddad JG. Osteopetrorickets. The paradox of plenty. Pathophysiology and treatment. *Clin Orthop* 1993;294:64–78.
- Felix R, Hofstetter W, Cecchini MG. Recent developments in the understanding of the pathophysiology of osteopetrosis. *Eur J Endocrinol* 1996;134:143–56.
- Solh H, Da CA, Giri N, *et al*. Bone marrow transplantation for infantile malignant osteopetrosis. *J Pediatr Hematol Oncol* 1995;17:350–5.



Malignant infantile osteopetrosis presenting with neonatal hypocalcaemia

Madhusudan Srinivasan, Mario Abinun, Andrew J Cant, et al.

Arch Dis Child Fetal Neonatal Ed 2000 83: F21-F23

doi: 10.1136/fn.83.1.F21

Updated information and services can be found at:

<http://fn.bmj.com/content/83/1/F21.full.html>

These include:

References

This article cites 18 articles, 7 of which can be accessed free at:

<http://fn.bmj.com/content/83/1/F21.full.html#ref-list-1>

Email alerting service

Receive free email alerts when new articles cite this article. Sign up in the box at the top right corner of the online article.

Topic Collections

Articles on similar topics can be found in the following collections

[Calcium and bone](#) (13 articles)
[Metabolic disorders](#) (186 articles)
[Child health](#) (992 articles)
[Rheumatology](#) (41 articles)
[Artificial and donated transplantation](#) (11 articles)
[Immunology \(including allergy\)](#) (259 articles)

Notes

To request permissions go to:

<http://group.bmj.com/group/rights-licensing/permissions>

To order reprints go to:

<http://journals.bmj.com/cgi/reprintform>

To subscribe to BMJ go to:

<http://group.bmj.com/subscribe/>