

CASE REPORT

Neonatal pneumatocele as a complication of nasal continuous positive airway pressure

H M A de Bie, L van Toledo-Eppinga, J I M L Verbeke, R M van Elburg

Arch Dis Child Fetal Neonatal Ed 2002;**86**:F202–F203

A preterm infant with mild respiratory insufficiency resulting from respiratory distress syndrome developed a pneumatocele after the start of nasal continuous positive airway pressure. Pneumonia was excluded by sputum and blood cultures. Treatment with high frequency oscillation ventilation resulted in complete recovery.

A preterm infant was admitted to the neonatal intensive care unit because of progressive respiratory insufficiency. He was born in another hospital after 34 weeks gestation by caesarean section because of a transverse lie. Steroids had not been administered antenatally. Membranes were ruptured for less than 24 hours. Apgar scores were 7, 7, and 10 after 1, 5, and 10 minutes respectively, and humidified oxygen was provided for several minutes. No bag and mask ventilation was required. Birth weight was 2460 g (50th percentile (weight according to gestational age)).

The patient developed signs of respiratory distress several hours after birth consisting of nasal flaring, grunting, intercostal and subcostal retractions, and tachypnoeic respiration with increased oxygen requirement until 60%. Breath sounds were normal. A chest radiograph suggested respiratory distress syndrome I–II (fig 1). Differential diagnosis included group B streptococcal pneumonia or wet lung. The patient was treated with continuous positive airway pressure (CPAP) with extra

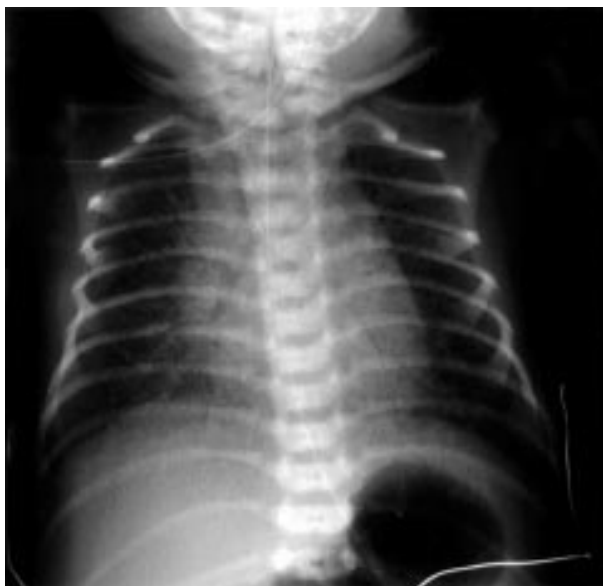

Figure 1 Radiograph taken several hours after birth suggesting respiratory distress syndrome I–II. No other abnormalities can be seen.

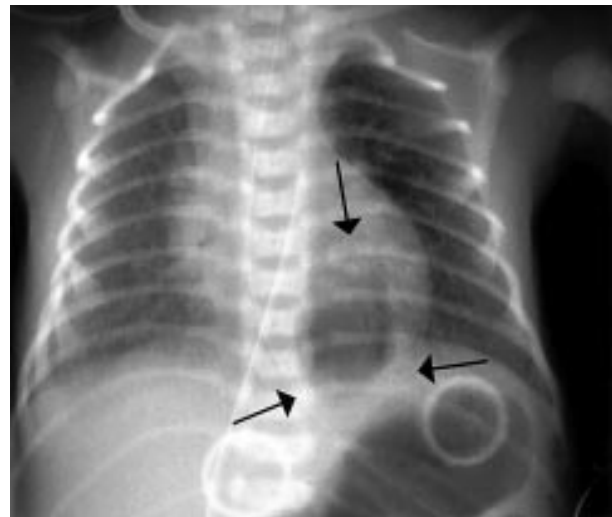


Figure 2 Radiograph taken on admission to the neonatal intensive care unit, showing a cyst located retrocardially.

oxygen through nasal prongs (Babylog; Dräger Medizintechnik, Lübeck, Germany). CPAP was initiated five hours after birth. The patient was suctioned with a controlled length of suction catheter, excluding the possibility that the pneumatocele had been caused by improper suction. After blood cultures and nasopharyngeal aspirate had been taken, antibiotics were administered because pneumonia could not be excluded. During the next 48 hours, the patient developed progressive respiratory insufficiency with increasing oxygen requirement to 70% despite the positive end expiratory pressure being raised from 4 cm H₂O to 6 cm H₂O. Although the clinical situation deteriorated, capillary blood gases remained stable, with pH between 7.32 and 7.36, carbon dioxide levels between 5.6 and 6.2 kPa, and bicarbonate levels between 23.1 and 23.5 mmol/l.

Twenty four hours after birth the chest radiograph showed a progressive cyst located retrocardially (fig 2). Thoracic computed tomography showed a cystic malformation located retrocardially, which had its origin in a proximal bronchus. There was no connection to the lung parenchyma. Other parts of the lung did not show any abnormalities (fig 3). A diagnosis of pneumatocele due to increased airway pressure from CPAP was made.

DISCUSSION

In neonates, pneumatocele formation is described as a complication of pneumonia. It is reported to occur after infection with *Staphylococcus aureus*, *Streptococcus pneumoniae*, *Enterobacter cloacae*, *Escherichia coli*, *Klebsiella pneumoniae*, or *Pseudomonas aeruginosa*.^{1–3} It has also been described as a

Abbreviations: CPAP, continuous positive airway pressure; HFOV, high frequency oscillation ventilation

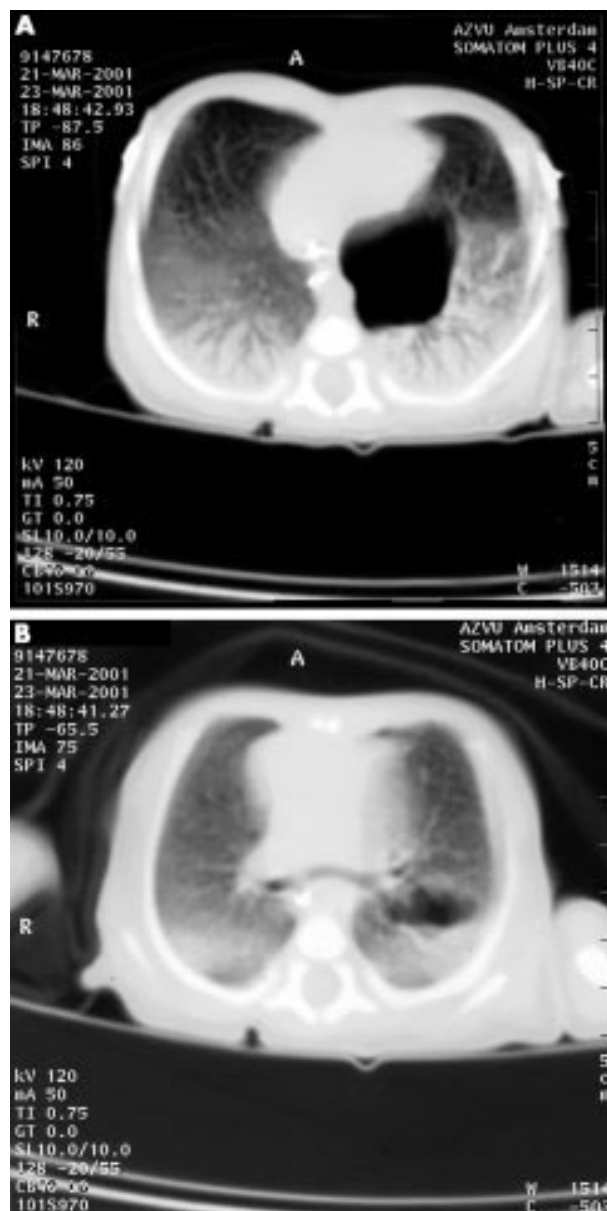


Figure 3 Thoracic computed tomography showing the cystic malformation located retrocardially with its origin in a proximal bronchus without connection to the lung parenchyma. Other parts of the lung are normal.

complication of artificial ventilation in older children and adults.^{4,5} Therapeutic options include appropriate intravenous antimicrobial treatment. If this fails, surgery may be necessary.⁶⁻⁹ Several invasive methods have been described. Decompression by percutaneous computed tomographic guided catheter placement or direct tube thoracostomy have

been suggested as well as surgical resection of the pneumatocele. Complications of surgical intervention include pulmonary abscess and persistent fistula.⁴ Little information is available about the natural history of pneumatoceles. Rupture and development of tension pneumothorax have been described in an older patient.⁴ However, to our knowledge, no large series of neonates with pneumatoceles have been described.

In our patient, the pneumatocele was located centrally, which complicates surgical resection and percutaneous catheter related decompression. We chose to treat him with high frequency oscillation ventilation (HFOV; Sensormedics 3100A, Bilthoven, The Netherlands), which produces compression of the pneumatocele and distention in other parts of the lung. The initial continuous distending pressure was 13 cm H₂O and the amplitude 33 cm H₂O with a normal volume HFOV strategy. Gradually decreasing the continuous distending pressure caused the pneumatocele to reduce in size and finally disappear after 10 days. Surfactant was not given. Cultures of blood and nasopharyngeal aspirate remained negative, confirming CPAP as the cause of the pneumatocele.

In conclusion, this report describes a neonate who developed a pneumatocele as a complication of CPAP. HFOV was found to be an efficient, non-invasive treatment. Another non-invasive option that can be used if HFOV fails to resolve the pneumatocele may be selective intubation and ventilation of a main bronchus.

Authors' affiliations

H M A de Bie, L van Toledo-Eppinga, J I M L Verbeke, R M van Elburg, Department of Pediatrics, Vrije Universiteit Medical Centre, Amsterdam, The Netherlands

Correspondence to: Dr de Bie, Department of Pediatrics, Vrije Universiteit Medical Centre, PO Box 7057, 1007 MB Amsterdam, The Netherlands; b.debie@vumc.nl

Accepted 22 January 2002

REFERENCES

- 1 **Glustein JZ**. *Enterobacter cloacae* causing pneumatocele in a neonate. *Acta Paediatr* 1994;**83**:990-1.
- 2 **Papageorgiou A**, Bauer CR, Fletcher BD, *et al*. Klebsiella pneumonia with pneumatocele formation in newborn infant. *Can Med Assoc J* 1973;**109**:1217-19.
- 3 **Bermejo VE**, Gonzales ME, Martinez AM, *et al*. Pneumatocele as a complication of *E. coli* pneumonia in a newborn infant. *An Esp Pediatr* 1992;**37**:526-8.
- 4 **Hunt JP**, Buechter KJ, Fakhry SM. *Acinetobacter calcoaceticus* pneumonia and the formation of pneumatoceles. *J Trauma* 2000;**48**:964-70.
- 5 **Wagner PK**, Knoch M, Sangmeister C, *et al*. Extracorporeal gas exchange in adult respiratory distress syndrome: associated morbidity and its surgical treatment. *Br J Surg* 1990;**77**:1395-8.
- 6 **Al-Bassam A**, Al-Rabeeah A, Al-Nassar S, *et al*. Congenital cystic disease of the lung in infants and children. *Eur J Pediatr Surg* 1999;**9**:364-8.
- 7 **Seo T**, Ando H, Watanabe Y, *et al*. Acute respiratory failure associated with intrathoracic masses in neonates. *J Pediatr Surg* 1999;**34**:1633-7.
- 8 **Kogutt MS**, Lutrell CA, Puyau FA, *et al*. Decompression of pneumatocele in a neonate by percutaneous catheter placement. *Pediatr Radiol* 1999;**29**:488-9.
- 9 **Shamberger RC**, Wohl ME, Perez-Atayde A, *et al*. Pneumatocele complicating hyperimmunoglobulin E syndrome (Job's syndrome). *Ann Thorac Surg* 1992;**54**:1206-8.



Neonatal pneumatocele as a complication of nasal continuous positive airway pressure

H M A de Bie, L van Toledo-Eppinga, J I M L Verbeke, et al.

Arch Dis Child Fetal Neonatal Ed 2002 86: F202-F203

doi: 10.1136/fn.86.3.F202

Updated information and services can be found at:

<http://fn.bmj.com/content/86/3/F202.full.html>

These include:

References

This article cites 9 articles, 1 of which can be accessed free at:

<http://fn.bmj.com/content/86/3/F202.full.html#ref-list-1>

Email alerting service

Receive free email alerts when new articles cite this article. Sign up in the box at the top right corner of the online article.

Topic Collections

Articles on similar topics can be found in the following collections

[Child health](#) (992 articles)

[Infant health](#) (591 articles)

[Neonatal health](#) (636 articles)

[Pneumonia \(infectious disease\)](#) (24 articles)

[Pneumonia \(respiratory medicine\)](#) (23 articles)

[TB and other respiratory infections](#) (45 articles)

Notes

To request permissions go to:

<http://group.bmj.com/group/rights-licensing/permissions>

To order reprints go to:

<http://journals.bmj.com/cgi/reprintform>

To subscribe to BMJ go to:

<http://group.bmj.com/subscribe/>