

PostScript

LETTERS

If you have a burning desire to respond to a paper published in *ADC* or *F&N*, why not make use of our "rapid response" option?

Log on to our website (www.archdischild.com), find the paper that interests you, click on "full text" and send your response by email by clicking on "submit a response".

Providing it isn't libellous or obscene, it will be posted within seven days. You can retrieve it by clicking on "read eletters" on our homepage.

The editors will decide, as before, whether to also publish it in a future paper issue.

Intramuscular injection of propacetamol in a neonate

Neonatal paracetamol poisoning is rare and usually the result of maternal poisoning before birth.¹ We report the case of a neonate who received a high dose of propacetamol chlorhydrate by intramuscular injection.

The baby was born at 41 weeks gestation, weighing 3780 g, after a 12 hour labour marked by maternal fever. He was treated for infection with intramuscular injections of ampicillin and gentamicin. On the first day of life, he was accidentally given an intramuscular injection of 2 ml of a dilution of propacetamol chlorhydrate in 9% NaCl containing 800 mg (211 mg/kg) propacetamol, equivalent to 105.5 mg/kg paracetamol. The infant was then transferred to our unit.

As soon as he arrived, he received an intravenous bolus of 150 mg/kg N-acetylcysteine over 15 minutes, and then a perfusion of 50 mg/kg N-acetylcysteine over the next four hours. The first plasma paracetamol concentration, measured four hours after the injection, was below the toxic level (49 mg/l).²

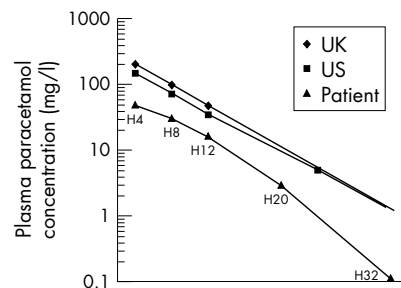


Figure 1 Evolution of plasma paracetamol concentration compared with toxicity nomograms.² H4, H8, H12, H20, and H32 indicate the number hours after N-acetylcysteine injection. UK, United Kingdom nomogram; US, United States nomogram.

Concentrations measured at eight, 12, 20, and 32 hours after the later injections showed a slow decrease (fig 1). The perfusion of N-acetylcysteine was continued at 100 mg/kg/24 hours for 22 hours until the plasma paracetamol concentration reached 3 mg/l. The liver enzymes and the coagulation profile remained normal during the hospital stay and seven days after discharge. No local complication at the injection site occurred besides induration. No adverse effect of N-acetylcysteine was noted.

There are very few data about intramuscular injection of propacetamol, and no data for the neonate. In our observation, the calculated half life was 3.5 hours, similar to that after intravenous injection.³ Given the very slow decrease in plasma paracetamol concentration during the first eight hours, we suggest that, in neonates, after intramuscular injection of a high dose of propacetamol, N-acetylcysteine should be administered even if the early plasma paracetamol concentration is below toxicity level, and continued until the plasma paracetamol concentration reaches the therapeutic level (3–10 mg/l).³

P Nolent

Neonatal and Pediatric Intensive Care unit, Trousseau Hospital For Children, 26 Av Du Dr Netter, 75571 Paris Cedex 12, France; paul.nolent@trs.ap-hop-paris.fr

References

- 1 Arana A, Morton NS, Hansen TG. Treatment with paracetamol in infants. *Acta Anaesthesiol Scand* 2001;**45**:20–9.
- 2 Routledge P, Vale JA, Bateman DN, et al. Paracetamol (acetaminophen) poisoning. No need to change current guidelines to accident departments. *BMJ* 1998;**317**:1609–10.
- 3 Autret E, Dutertre JP, Breteau M, et al. Pharmacokinetics of paracetamol in the neonate and infant after administration of propacetamol chlorhydrate. *Dev Pharmacol Ther* 1993;**20**:129–34.

Placement of neonatal central venous catheter tips: is the right atrium so dangerous?

The debate about placement of central venous catheter tips in neonates¹ leaves me puzzled. We have been using percutaneously placed central venous catheters in our unit since 1978, with the aim of tip placement in the right atrium achieved in 58% of catheters. I have prospectively maintained records of every baby, their diagnoses, managements (including central venous catheter use), and complications treated here since 1983. These records cover the period 1 January 1984 to 31 December 2001 and encompass 2044 catheters placed in 1738 babies, for a total of 33 014 days. The longest life of any single catheter has been 99 days. I have never seen the complication of cardiac tamponade from one of these catheters. Why? Some may suggest we have "missed" it. I think not. I would suggest the following:

- (1) All catheters are placed by experienced personnel, consultant or senior registrar.
- (2) No catheter is ever left in a position where it does not easily and repeatedly withdraw blood.

(3) All catheters are injected with radio-opaque dye to ascertain tip placement (the ostensibly "radio-opaque" catheters are not in fact radio-opaque, only less radiolucent than the non-radio-opaque catheters, and cannot be clearly seen within the mediastinal structures²). We use by preference, and virtually exclusively, the radiolucent catheter "Epicutaneo-cave catheter" (Vygon).

(4) Dye injection should preferably continue while the radiograph is taken so a blush of dye can be seen exiting the end of the catheter, confirming it is not caught up within interstices in vessels or cardiac chambers.

The evidence against right atrial placement seems to be based on anecdotal experience of catheters which are mostly known to be inappropriately placed, as your correspondent states "accompanied by angulation, curvature, or looping of the line".¹ I would not like to expose my patients to a "small risk of thrombosis or hydrothorax" because of some legal imperative derived from dogmatic pronouncements based on a small number of adverse experiences. The true problem seems to be failure to adequately assess line placement, not proper placement free in the right atrium.

D W Cartwright

Director of Neonatology, Royal Women's Hospital, Brisbane, Australia; David.Cartwright@Health.qld.gov.au

Reference

- 1 Darling JC, Newell SJ, Dear PRF. Placement of neonatal central venous catheter tips in the right atrium: a practice to be avoided? *Arch Dis Child Fetal Neonatal Ed* 2001;**85**:F146.
- 2 Reece A, Ubhi T, Craig AR, et al. Positioning long lines: contrast versus plain radiography. *Arch Dis Child Fetal Neonatal Ed* 2001;**84**:F129–30.

Author's reply

Dr Cartwright disagrees with our recommendation¹ to avoid right atrial central venous catheter tip placement based on 2000 catheters without tamponade. We agree that vigilant use of catheters (including radio-opaque dye to confirm placement), by experienced personnel aware of the potential risks, makes tamponade a rare complication, even when right atrial placement is used routinely. We have recently published a paper² to increase awareness of the risk of tamponade and to warn against right atrial tip placement. In addition, for practitioners who continue to use right atrial placement, we wished to highlight the hitherto little publicised message that any line curvature within the atrium is unacceptable, because it denotes tip trapping in the myocardial wall and therefore a significant risk of tamponade. We are concerned that Dr Cartwright's letter should go unchallenged, because unfortunately his experience is not as reassuring as it may at first seem. In addition, we wish to draw attention to a recent Department of Health Review of four neonatal deaths by cardiac tamponade related to central venous catheter use.³ One of the conclusions was that right atrial tip placement should be avoided.

A recent retrospective five year survey in the United Kingdom has estimated a risk of

1.6 tamponades per 1000 neonatal percutaneous central venous catheter lines inserted, and that about 8000 such catheters are inserted annually in the United Kingdom.⁴ If we take the mortality of tamponade to be between 45%⁴ and 65%,² then each year in the United Kingdom, six to eight neonates die because of tamponade related to central venous catheter placement. This value is likely to be a considerable underestimate because it is based on retrospective data, and cases may be missed if routine postmortem examination is not performed. Each of these deaths is preventable by avoiding right atrial tip placement. Although Dr Cartwright's series indicates that in his practice the risk of tamponade is less than 0.5 per thousand lines inserted, he presumably would accept that some risk remains, as tip position cannot be monitored continuously, line migration is known to occur, and tamponade may occur within hours of tip trapping. Even careful radiographic monitoring with use of radioopaque dye will not reveal line curvature in

the plane of the radiographs, and we and others who advocate dye would usually only inject it at the time of initial placement rather than on a regular basis.⁵

The key question is whether this low risk of an often fatal complication of a common neonatal procedure is acceptable, when the risk can be reduced to zero by avoiding right atrial tip placement altogether. As Dr Cartwright points out, the cost of this risk reduction may be an increase in the risk of thrombosis and hydrothorax, but these complications are rare, and hardly ever fatal. They are surely negligible when balanced against the cost (in lives lost) of tamponade. We believe that the argument against right atrial tip placement is compelling. Ignore it at your patients' peril.

J C Darling
S J Newell
P R F Dear

Department of Paediatrics and Child Health,
Clinical Sciences Building, St James's University
Hospital, Leeds LS9 7TF, UK

References

- 1 **Darling JC**, Newell SJ, Dear PRF. Placement of neonatal central venous catheter tips in the right atrium: a practice to be avoided? *Arch Dis Child Fetal Neonatal Ed* 2001;**85**:F146.
- 2 **Darling JC**, Newell SJ, Mohamdee O, *et al*. Central venous catheter tip in the right atrium: a risk factor for neonatal cardiac tamponade. *J Perinatal* 2001;**21**:461-4.
- 3 **Wariyar UK**, Hallworth D. Review of four neonatal deaths due to cardiac tamponade associated with the presence of a central venous catheter. London: Department of Health, 2001. <http://www.doh.gov.uk/manchesterbabies/manchreport.pdf>
- 4 **Beardsall K**, White DK, Kelsall AWR. Pericardial effusions and cardiac tamponade associated with neonatal long lines: are they really a problem? *Abstracts of the Neonatal Society June 2001*. http://www.neonatalociety.org/original_pages/abstractsNott1.asp
- 5 **Reece A**, Uhbi T, Craig AR, *et al*. Positioning long lines: contrast versus plain radiography. *Arch Dis Child Fetal Neonatal Ed* 2001;**84**:F129-30.



Placement of neonatal central venous catheter tips: is the right atrium so dangerous?

D W Cartwright

Arch Dis Child Fetal Neonatal Ed 2002 87: F155-F156
doi: 10.1136/fn.87.2.F155-a

Updated information and services can be found at:
<http://fn.bmj.com/content/87/2/F155.2.full.html>

References

These include:

This article cites 3 articles, 1 of which can be accessed free at:
<http://fn.bmj.com/content/87/2/F155.2.full.html#ref-list-1>

Article cited in:
<http://fn.bmj.com/content/87/2/F155.2.full.html#related-urls>

Email alerting service

Receive free email alerts when new articles cite this article. Sign up in the box at the top right corner of the online article.

Notes

To request permissions go to:
<http://group.bmj.com/group/rights-licensing/permissions>

To order reprints go to:
<http://journals.bmj.com/cgi/reprintform>

To subscribe to BMJ go to:
<http://group.bmj.com/subscribe/>