Downloaded from fn.bmj.com on February 10, 2012 - Published by group.bmj.com

SHORT REPORT

Contamination of a milk bank pasteuriser causing a *Pseudomonas aeruginosa* outbreak in a neonatal intensive care unit

C Gras-Le Guen, D Lepelletier, T Debillon, V Gournay, E Espaze, J C Roze

Arch Dis Child Fetal Neonatal Ed 2003;**88**:F434–F435

An environmental investigation and a cohort study were carried out to analyse an outbreak of infection caused by a serotype O10 *Pseudomonas aeruginosa* in a neonatal intensive care unit. Thirty one cases of infection were recorded, including four lethal ones. The outbreak was stopped by eradicating the environmental sources: a contaminated milk bank pasteuriser and bottle warmer.

We report an outbreak of nosocomial *Pseudomonas aeruginosa* infection that affected 31 patients in a 60 bed neonatology and neonatal intensive care unit between July 2000 and September 2001 (fig 1). Fourteen patients had symptomatic infection, and the remaining 17 only had gastrointestinal tract colonisation.

Table 1 gives the patient characteristics. The 14 symptomatic patients can be separated into three groups according to their gestation: seven very low birthweight preterm infants, two low birthweight preterm infants, and five full term infants. They can also be classified into three groups according to their clinical presentation. (a) Four patients presented with fulminant septicaemia and multiorgan failure. All these patients were very low birthweight preterm infants. Three infants died, two of them within the first few hours of symptom onset and one from multiorgan failure after six weeks. Blood cultures were positive for *P aeruginosa* O10. (b) In six patients, the infection developed from the respiratory tract, causing ventilatory status deterioration. Distal protected brush specimens were positive for *P aeruginosa* O10. One of these six infants (24 weeks postmenstrual age; birth weight 750 g) still has severe residual lung damage, and another (27 weeks postmenstrual age, birth weight 560 g) died from respiratory failure and refractory hypoxia. (c) In four patients, the presentation was an isolated discharge of pus from an ear. All of these patients were full term infants. Microscopic examination followed by myringotomy and microbiological studies established the diagnosis of acute otitis media caused by *P aeruginosa* O10. These four infants remained in good general health, with no evidence of sepsis. They recovered after 10 days of treatment with two appropriate antibiotics given intravenously (ceftazidime and amikacin) and locally (ofloxacin).

Table 1 Description of patients and clinical presentation according to gestation and birth weight

	Very low birth weight	Low birth weight	Full term
Number	7	2	5
Postmenstrual age (weeks)	25.1 (1.2)	30.8 (0.7)	39.6 (1.8)
Birth weight (g)	865 (45)	2163 (158)	2987 (482)
Fulminant septicaemia	4	0	0
Respiratory infection	3	2	1
Acute otitis media	0	0	4
Death	4	0	0

The outbreak was identified in June 2001. All the *P aeruginosa* isolates recovered during the outbreak were O10 serotype and were confirmed as a clonal strain by pulsed field gel electrophoresis. The strain was resistant to ticarcillin and susceptible to ceftazidime, imipenem, and all aminoglycosides. After this identification, new preventive measures were implemented to limit transmission by healthcare workers contaminated during care of infected or colonised patients. Infected or colonised patients were grouped in the same part of the unit,

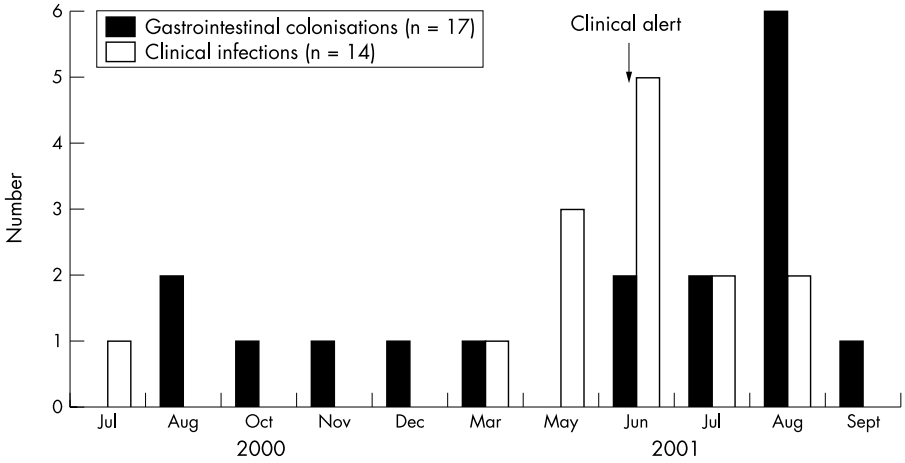

Figure 1 Epidemic curve. *Pseudomonas aeruginosa* O10 infections in a neonatal intensive care unit, 2000–2001.

Downloaded from fn.bmj.com on February 10, 2012 - Published by group.bmj.com

isolated from the other patients, and cared for by specific nurses not involved with other patients. Healthcare workers used hydro-alcoholic handrubs frequently and wore gloves while caring for the patients; in addition, they were trained in prevention of nosocomial infection. Despite these measures, new cases occurred, prompting a search for an environmental cause of the outbreak by the institutional committee of prevention of nosocomial infections. Swabs of the 69 water taps in the unit were negative for the causative organism. Finally, the milk bank pasteuriser, used to thaw the bottles of human donor milk and located three floors below the neonatal unit, was tested and found positive for the *P aeruginosa* O10 strain. This device was contaminating the outside of the bottles during thawing. Milk was only being routinely checked by bacteriological tests before being bottled and then frozen. These tests were not repeated after thawing. Subsequently, we found the same organism in the bottle warmer located in the unit and used to warm all the bottles used to feed the infants in the unit. Use of this milk bank pasteuriser and bottle warmer was discontinued immediately. Aseptic techniques during bottle handling were intensified.

The effectiveness of these measures was evaluated in October 2001 by screening stool specimens from all the patients in the department for *P aeruginosa* O10. At the time, three patients infected during the outbreak were still in the unit. All screening tests were negative. No further cases of *P aeruginosa* O10 infection were recorded.

DISCUSSION

Many *P aeruginosa* outbreaks in neonatal units have been reported.[1 2] This organism which is present in the environment is potentially invasive and highly virulent in very low birthweight preterm infants (< 28 postmenstrual weeks and birth weight < 1000 g); four of the seven patients in this category died (two of them only a few hours after symptom onset), whereas none of the seven older patients died (relative risk = 3.3 (95% confidence interval 1.3 to 8.6)). In four of the five full term infants, the infection was mild and consisted only of acute otitis media, which fully resolved after appropriate treatment with antibiotics. Thus patient related factors seem to play a major role in the prognosis of neonatal *P aeruginosa* infection.

During a sudden large outbreak such as that reported here (eight infections within a two month period), detection and prevention of patient to patient transmission is necessary but not sufficient. The detection of environmental contamination by painstaking detective work is also essential. The source of contamination must be looked for extensively even outside the unit concerned (the milk bank in our outbreak), not only in the products administered to the newborns but also on their containers.[3 4] These investigations should allow rapid implementation of appropriate preventive steps. The large number of potential sources of contamination is a major difficulty.[5 6] Milk bank contamination has not been reported previously. Neonatologists dealing with extremely fragile preterm infants should consider this possible source of contamination when several cases of life threatening infection caused by the same organism occur in a neonatal unit.

Authors' affiliations
C Gras-Le Guen, T Debillon, V Gournay, J C Roze, Département de périnatologie, Hôpital Mère-Enfant, CHU Nantes, France
D Lepelletier, Unité Opérationnelle d'Hygiène hospitalière, CHU Nantes
E Espaze, Laboratoire de Bactériologie, CHU Nantes

Correspondence to: Dr Roze, Service de réanimation pédiatrique et néonatale, Hôpital Mère Enfant, 9 quai Moncousu, 44099 Nantes Cedex, France; jeanchristophe.roze@chu-nantes.fr

Accepted 30 October 2002

REFERENCES

1 **Asay LD**, Koch R. Pseudomonas infections in infants and children. *N Engl J Med* 1960;**262**:1062–6.
2 **Foca M**, Jakob K, Whittier S, *et al*. Endemic Pseudomonas aeruginosa infection in a neonatal intensive care unit. *N Engl J Med* 2000;**343**:695–700.
3 **Moolenaar RL**, Crutcher JM, San Joaquin VH, *et al*. A prolonged outbreak of Pseudomonas aeruginosa in a neonatal intensive care unit: did staff fingernails play a role in disease transmission? *Infect Control Hosp Epidemiol* 2000;**21**:80–5.
4 **Archibald LK**, Ramos M, Arduino MJ, *et al*. Enterobacter cloacae and Pseudomonas aeruginosa polymicrobial bloodstream infections traced to extrinsic contamination of a dextrose multidose vial. *J Pediatr* 1998;**133**:640–4.
5 **Vochem M**, Vogt M, Doring G. Sepsis in a newborn due to Pseudomonas aeruginosa from a contaminated tub bath. *N Engl J Med* 2001;**345**:378–9.
6 **I Reiss**, A Borkhardt, R Fussle, A, *et al*. Disinfectant contaminated with Klebsiella oxytoca as a source of sepsis in babies. *Lancet* 2000;**356**:310.

Downloaded from fn.bmj.com on February 10, 2012 - Published by group.bmj.com

Contamination of a milk bank pasteuriser causing a *Pseudomonas aeruginosa* outbreak in a neonatal intensive care unit

C Gras-Le Guen, D Lepelletier, T Debillon, et al.

Arch Dis Child Fetal Neonatal Ed 2003 88: F434-F435
doi: 10.1136/fn.88.5.F434

Updated information and services can be found at:
http://fn.bmj.com/content/88/5/F434.full.html

These include:

References

This article cites 6 articles
http://fn.bmj.com/content/88/5/F434.full.html#ref-list-1

Article cited in:
http://fn.bmj.com/content/88/5/F434.full.html#related-urls

Email alerting service

Receive free email alerts when new articles cite this article. Sign up in the box at the top right corner of the online article.

Topic Collections

Articles on similar topics can be found in the following collections

Epidemiologic studies (529 articles)

Notes

To request permissions go to:
http://group.bmj.com/group/rights-licensing/permissions

To order reprints go to:
http://journals.bmj.com/cgi/reprintform

To subscribe to BMJ go to:
http://group.bmj.com/subscribe/